

Glottic Neurofibroma in an Elderly Patient: A Case Report

*Jiaying Liu, †Chin Fong Wong, *Francoise Lim, and *Jeeve Kanagalingam, *†Singapore, Singapore

Summary: Introduction. Neurogenic tumors of the larynx are extremely rare, accounting for less than 1% of all benign laryngeal tumors. The lesions that have been described in current literature are located either in the supraglottis or subglottis, mainly affecting the pediatric population and associated with von Recklinghausen disease.

Study Design. Descriptive study of an unusual case of an isolated neurofibroma of the glottis in an elderly patient with no history of neurofibromatosis.

Discussion. We discuss preoperative clues to the diagnosis, our surgical experience, and propose a theory of its pathogenesis originating from encapsulated nerve structures within the vocal fold.

Key Words: Neurofibroma–Laryngeal–Glottic–Vocal fold.

INTRODUCTION

Laryngeal neurofibromas are extremely rare. They account for 0.03–0.1% of benign tumors of the larynx.¹ Most of these lesions are located in the supraglottis and a small proportion in the subglottis. We describe an extremely rare case of a neurofibroma located in the vocal fold.

CASE REPORT

A 78-year-old man was referred to the Otolaryngology clinic for progressive voice hoarseness over 1 month associated with intermittent odynophagia but no weight loss. He was a chronic smoker and had a history of ischemic heart disease and gastroesophageal reflux.

Stroboscopic examination found a large cyst on the middle to posterior third of his right vocal fold (Figure 1). There was a persistent midportion chink caused by the cyst, which impeded glottic closure. The surrounding false folds, arytenoids, and arypepiglottic folds were mildly edematous consistent with laryngopharyngeal reflux. His hypopharynx and valleculae were normal.

A barium swallow done did not reveal any obstructive upper esophageal lesions. Despite a therapeutic course of proton pump inhibitors and voice therapy, the patient complained of worsening hoarseness and was keen for surgical excision of his vocal fold lesion.

Under general anesthesia, endoscopic laryngeal microsurgery was performed. A superior cordotomy was made lateral to the presumed cyst in the right vocal fold, following which a microflap was raised over the lesion maintaining a thin layer of overlying epithelium. The lesion measured 0.8 cm at its widest diameter and was thick walled enabling removal *in toto* (Figure 2). After excision, the microflap was replaced and 1 mL of hyaluronic acid was injected into the paraglottic space to augment the vocal fold and prevent glottic insufficiency.

Histological examination revealed a nodular lesion comprising spindle cells set in a myxoid stroma of collagen fibers (Figure 3A). Scattered mast cells were present. The spindle cells were positive for S100 indicating neurogenic origin (Figure 3B). There was no dysplasia or evidence of malignancy. These features were in keeping with a vocal fold neurofibroma.

Postoperatively, the patient's voice improved. Repeat stroboscopy at 6 months after surgery showed a healed right vocal fold and mucosal wave is close to normal.

DISCUSSION

Neurogenic tumors of the larynx are extremely rare. They account for 0.1–1.5% of all benign laryngeal tumors, with neurofibromas being less common than schwannomas.¹ To date, fewer than 30 cases of endolaryngeal neurofibromas have been reported in the English literature since its first description by Hollinger in 1950. Most of these lesions have been reported in the pediatric population and in association with von Recklinghausen disease. Our patient differs from this conventional profile as he is elderly and has no personal or family history of von Recklinghausen disease.

Clinically, women are more affected with a male to female ratio of 2:3.² Its presenting symptoms are variable depending on patient's age and size and location of the lesion. Children often present with stridor, whereas adults present with a variety of symptoms ranging from progressive voice hoarseness to dyspnea and even vague throat discomfort on swallowing. Hence, speech and swallowing assessment are an essential part of the workup for any patient with endolaryngeal lesions.

The glottic neurofibroma in this case appeared as a unilateral smooth submucosal swelling on the posterior third of vocal fold, which impaired vocal fold mobility on stroboscopy. Malignant pathology was less of a consideration as the lesion did not display infiltrative characteristics, multifocality, or cartilage erosion. A few benign submucosal laryngeal pathologies were considered and systematically eliminated. A laryngocele was unlikely as they are found in the paramedian position. Paragangliomas tend to have a supraglottic or paraglottic location rather than at the glottis. Papillomas are found on the anterior third rather than posterior portion of the vocal fold, and rheumatoid arthritis nodules are bilateral with associated erosion of the cricoarytenoid and cricothyroid joints. The final possible differential in a well-defined solitary submucosal mass is a neurogenic

Accepted for publication February 6, 2013.

From the *Department of Otolaryngology, Tan Tock Seng Hospital, Singapore, Singapore; and the †Department of Pathology, Tan Tock Seng Hospital, Singapore, Singapore.

Address correspondence and reprint requests to Jiaying Liu, Department of Otolaryngology, Tan Tock Seng Hospital, 11 Jalan Tan Tock Seng, Singapore 308433, Singapore. E-mail: liu.jiaying@sgh.com.sg

Journal of Voice, Vol. ■, No. ■, pp. 1-3
0892-1997/\$36.00

© 2013 The Voice Foundation

<http://dx.doi.org/10.1016/j.jvoice.2013.02.002>

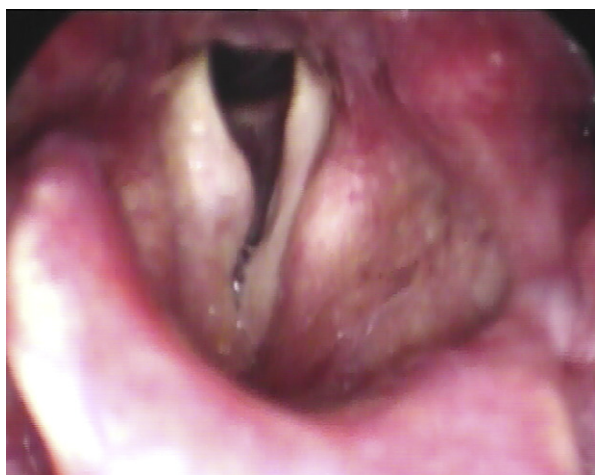

FIGURE 1. Video still of right vocal fold lesion during stroboscopy.

tumor. In retrospect, this process of elimination could have been our only clue to the nature of this lesion.

Laryngeal neurofibromas frequently affect the supraglottis, namely the arytenoid, aryepiglottic fold, and false folds^{2,3} because it is believed that neurofibromas arise from the terminal ramifications of the superior laryngeal nerve in the submucosal space.^{4,5} When they arise in the subglottis, their origin is from the recurrent laryngeal nerve.⁶ The lesion in our patient was isolated to the glottis and we postulate that a neurofibroma can arise from the encapsulated nerve structure in the vocal fold. In 1989, the human vocal fold was confirmed by Nagai⁷ to have encapsulated nerve structures. These structures were located in the connective tissue of the vocalis muscle as well as the subepithelium of the cartilaginous part of the vocal fold. Further examination under electron microscopy revealed that these encapsulated nerve structures contained abundant axon terminals, dense collagen, a striated muscle fiber, and several side branches of nonmyelinated nerve fibers. This complex milieu of neural and fibrous tissue is consistent with the characteristic histologic appearance of neurofibromas whose characteristic features are spindle cells with wavy nuclei, collagen, and trapped nerve fibers. Apart from histological features, a positive immunohistochemical

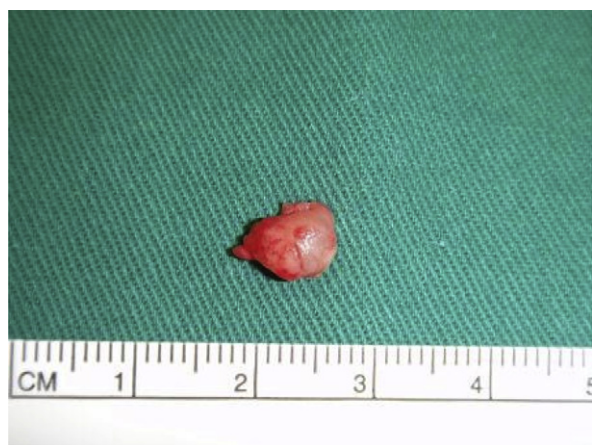

FIGURE 2. Lesion removed *in toto* from right vocal fold.

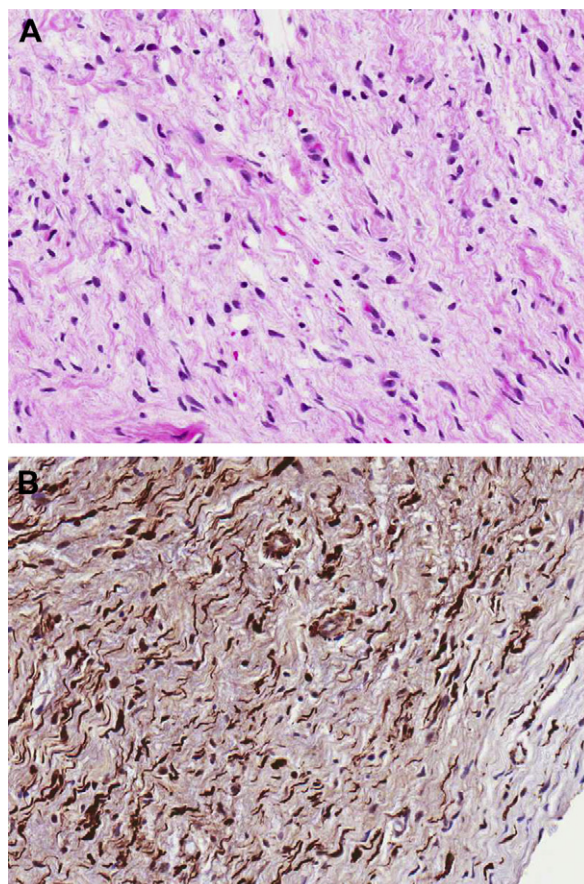


FIGURE 3. A. Histological photography demonstrating wavy spindle cells within a stroma of collagen fibers. B. Spindle cells staining positive with S100 immunohistochemical stain.

staining for S100 protein helps confirm diagnosis of a neurogenic tumor.

Neurofibromas have been reported in the literature to be surgically difficult to separate from normal tissue because they lack a well-defined capsule and are instead made up of a mesh of interwoven spindle cells, axons, and collagen fibers.¹ In our experience with this glottic neurofibroma, we found it extremely easy to dissect the fibrous capsule of this lesion off the underlying vocal ligament, successfully removing it *in toto*.

All reported cases of endolaryngeal neurofibromas were diagnosed retrospectively after laryngeal surgery and this case is no exception. Our experience with this patient has taught us that the presence of a well-defined unilateral submucosal mass, which impairs vocal fold mobility on stroboscopic examination, should raise the suspicion of a neurogenic tumor. There is currently no fixed consensus on the management algorithm for these tumors. It would suffice to conclude that surgical removal is necessary for treatment and the most crucial factor in selection of the surgical method is the histological type of the neurofibroma. Nonplexiform neurofibromas have a good prognosis after excision if complete removal is achieved at the primary surgery.⁸ However, plexiform neurofibromas, which are pathognomonic of neurofibromatosis, carry malignant potential and require extensive surgical

exposure to get wide and clear margins. Complete extirpation in diffuse tumors may even require aggressive external approaches such as lateral pharyngotomy, laryngotomy, or lateral thyrotomy.⁹

REFERENCES

1. Jones SR, Myers EN, Barnes L. Benign neoplasms of the larynx. *Otolaryngol Clin North Am.* 1984;17:151–178.
2. Supance JS, Queneue DJ, Crissman J. Endolaryngeal neurofibroma. *Otolaryngol Head Neck Surg.* 1980;88:74–78.
3. Chang-Lo M. Laryngeal involvement in von Recklinghausen's disease: a case report and review of the literature. *Laryngoscope.* 1977;87:435–472.
4. Maisel RH, Ogura JH. Neurofibromatosis with laryngeal involvement. *Laryngoscope.* 1974;84:132–140.
5. Jasper BW, Stern FA. Neurofibroma of the larynx occurring with von Recklinghausen disease: report of a case. *Arch Otolaryngol.* 1973;98:77–79.
6. Fukuda I, Ogasawara H, Kumoi T, Sugihara K, Wada H. Subglottic neurofibroma in a child. *Int J Pediatr Otorhinolaryngol.* 1987;14:161–170.
7. Nagai T. Confirmation of encapsulated nerve structures in the vocal cord. *Acta Otolaryngol.* 1989;107:278–282.
8. Maship MJ, Esteban E, Alberto C, Menor E, Cortina H. Laryngeal involvement in pediatric neurofibromatosis: a case report and review of the literature. *Pediatr Radiol.* 1996;26:488–492.
9. Nakahira M, Nakatani H, Sawada S, Matsumoto S. Neurofibroma of the larynx in neurofibromatosis. *Arch Otolaryngol Head Neck Surg.* 2001;127:325–328.