

# Treatment of Anaplastic Thyroid Carcinoma: How much is too much?

Lim Quan Qing Richmond<sup>1</sup>, C. G. L. Hobbs<sup>1</sup>, Kanagalingam Jeevendra<sup>1</sup>  
<sup>1</sup> Department of Otorhinolaryngology, Tan Tock Seng Hospital



## Introduction

Anaplastic thyroid carcinomas comprise a small proportion of all thyroid cancers. While thyroid cancers in general have good prognosis with up to 90% 10-year survival rate, anaplastic carcinomas comprising 1-2% of thyroid cancers have dismal prognosis with median survival of 4 months.

This poster aims to examine the treatment and prognosis of this rare cancer.

## Results

**Demographics:** There were 4 males and 3 females. Age ranged from 65 to 81 (median 74).

**Presentation:** All patients presented with a visible neck lump. 2 patient had hoarseness of voice and 6 patients had compressive symptoms comprising either stridor or dysphagia.

**Investigations:** All cases were worked up with 1) FNAC followed by 2) CT scan.

1) Anaplastic pathology was suspected or confirmed on FNAC in all but 1 patient with a non-diagnostic FNAC.

2) Extrathyroidal primary lesions (T4b) were observed on CT scan in 3 patients. Nodal metastasis (N1) was seen in 6/7 patients. 4 patients had distant metastasis (M1) at presentation (Fig. 1).

**Staging:** 3/7 patients had stage IVb disease and 4/7 patients had stage IVc disease.

**Outcome:** Of the 3 patients with stage IVb disease, all received surgery with curative intent, 2 received EBRT (1 was free of disease when last followed up 44 months post-op, the other died 2.6 months post-op) while the last defaulted EBRT and was subsequently lost to follow up. One with stage IVc disease and extensive metastasis did not receive surgery. Survival was 0.8 months. The remaining 3 patients with stage IVc tumours received palliative surgery and 2 received EBRT (survival 1.6 months with surgery and EBRT, 2 months with surgery alone) (Fig. 2).

**Morbidity:** 6 patients received surgery. Post-operatively, 1 patient had transient hypocalcemia. 3 patients had vocal cord palsy (2 were present before surgery and were secondary to recurrent laryngeal nerve involvement while the third was transient). 1 patient required tracheostomy. 3 patients had residual tumours due to inadequate resection. 2 patients had recurrences despite adequate resection margins (Fig. 3).

## Discussion

FNAC is an accurate tool for preliminary tissue diagnosis of anaplastic carcinomas.

Staging of anaplastic carcinomas with CT scans is reliable for N staging, but less so for T staging (Fig. 4).

Anaplastic carcinomas remain extremely difficult to treat as they often present late in the course of the disease. In contrast, patients who present early before nodal spread occurs have a good chance of survival, despite the fact that staging of anaplastic carcinomas is independent of node status (the only patient who was free of disease at last follow up had no nodal metastasis on presentation).

In patients with metastatic disease, aggressive treatment with surgery and adjuvant radiotherapy seem to marginally prolong survival at the cost of significant morbidity and complications.

## Methods

A retrospective review of 153 patients with thyroid carcinoma treated between 1998 and 2009 in a tertiary referral ENT unit in Tan Tock Seng Hospital, Singapore was done. Of these, a total of 7 patients were diagnosed with anaplastic carcinoma on postoperative histology/FNAC.

These patients were further analysed with regard to demographics, presentation, investigations, management and treatment outcomes.

Fig.1: Location of Metastasis

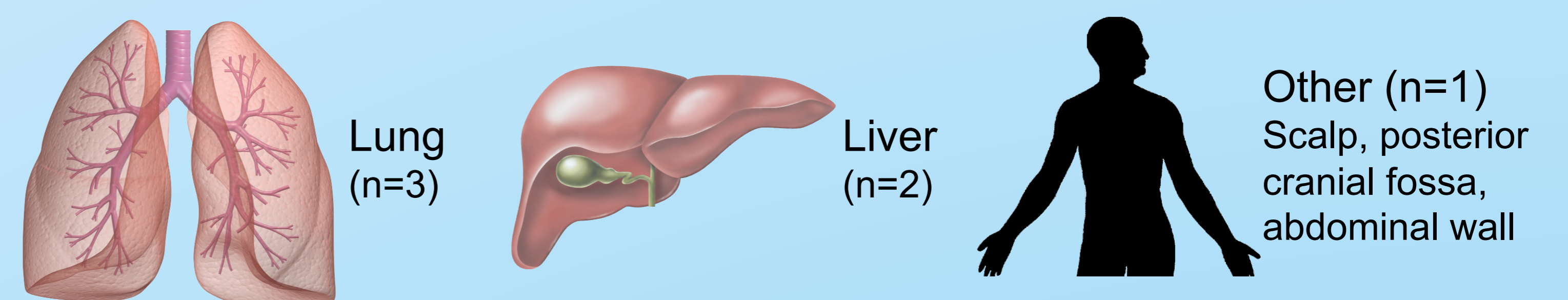


Fig. 2: Outcomes

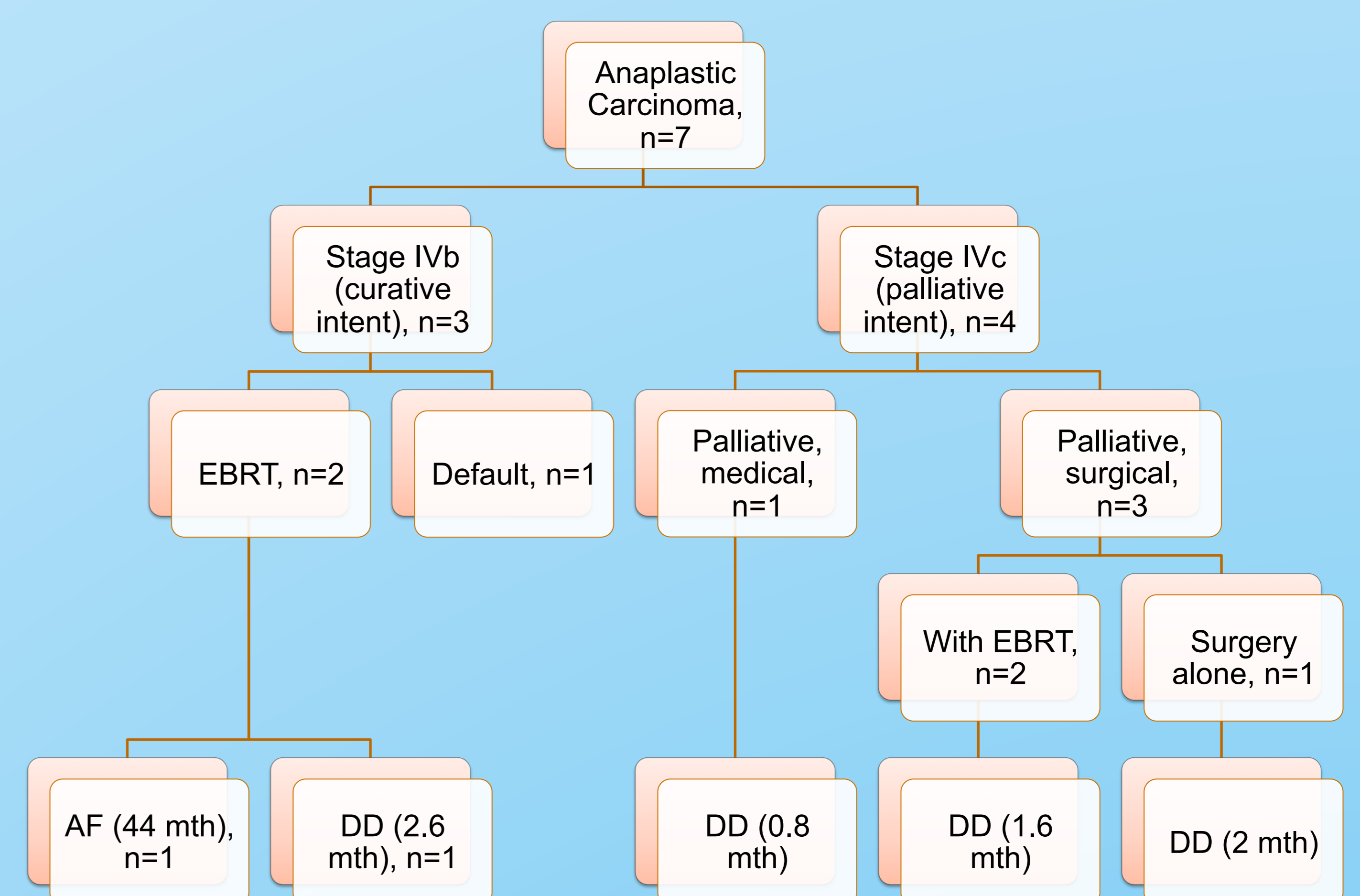


Fig. 3: Rate of post-operative complications

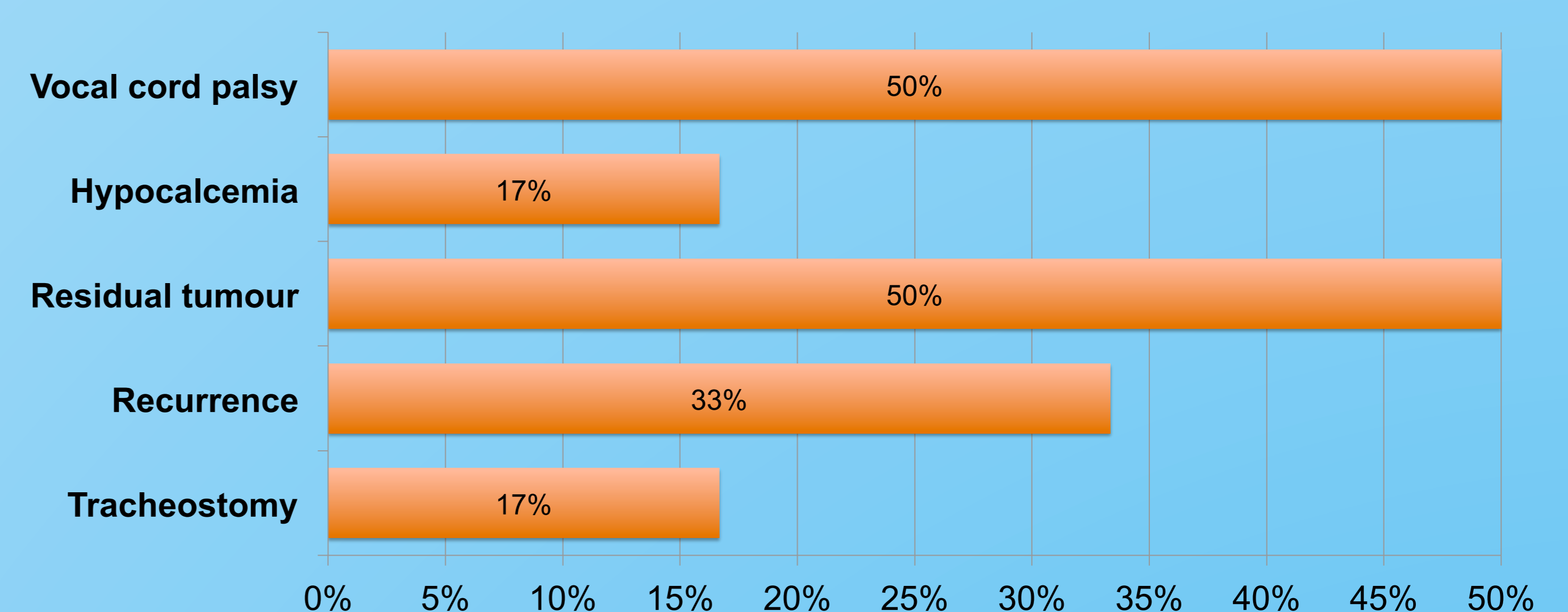
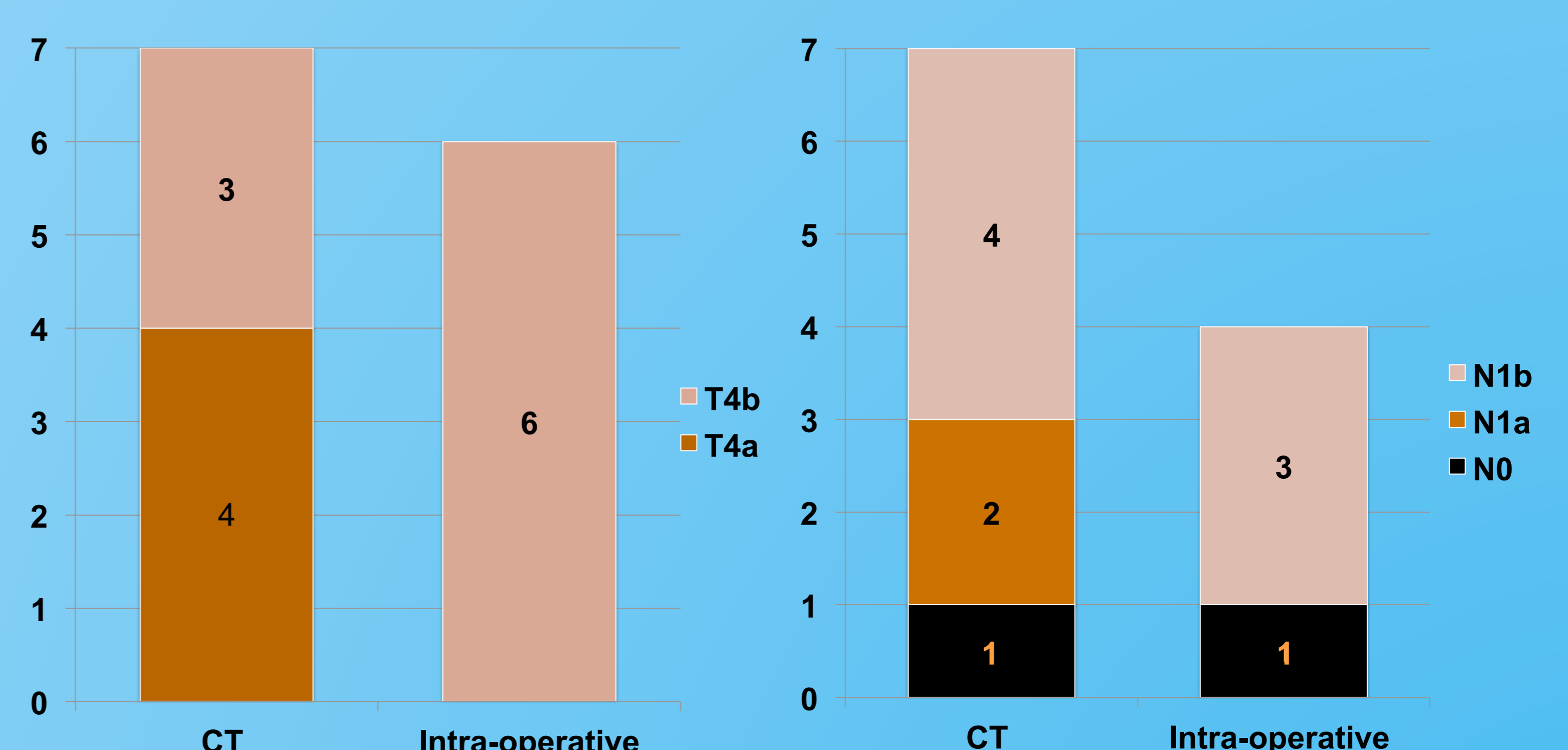


Fig. 4: Correlation between CT and intra-operative findings



1 patient did not have surgery and 3 patients did not have node clearance